

## Presenting With Persistent HIV Viremia

Schinold, Michael<sup>1</sup>; Kogilwaimath, Siddharth<sup>1,2</sup>; Fitzgerald, Naomi<sup>3</sup>; Pozniak, Carley<sup>4</sup>

<sup>1</sup>College of Medicine, University of Saskatchewan, Saskatoon, Canada ; <sup>2</sup>Department of Medicine, University of Saskatchewan, Saskatoon, Canada ; <sup>3</sup> Department of HIV Medicine, Guy's and St. Thomas' NHS Foundation Trust, London, United Kingdom ; <sup>4</sup>Department of Pharmacy, Saskatchewan Health Authority, Saskatoon, Canada

### Case Description

A 54-year-old male presented to our hospital in March 2018 with a several week history of feeling unwell with anorexia, 25 kg unintentional weight loss, dyspnea and odynophagia. He was diagnosed with HIV and had an initial CD4 of 9 (1.8%) and HIV viral load of 333,692 copies/mL. He was concurrently diagnosed with pneumocystis pneumonia (PCP), disseminated *Mycobacterium avium* complex (dMAC) infection, CMV retinitis and esophageal candidiasis.

The patient was initiated on antiretroviral therapy on April 24th, 2018 with Descovy (Emtricitabine and Tenofovir Alafenamide [TAF]) and Dolutegravir but was soon switched to Truvada (Emtricitabine and Tenofovir disoproxil fumarate [TDF]) with Dolutegravir once dMAC was diagnosed, due to drug interactions with Rifabutin. He was concurrently being treated for dMAC with Azithromycin, Rifabutin and Ethambutol. He completed a course of treatment with Trimethoprim-Sulfamethoxazole for PCP followed by secondary prophylaxis. He was treated with Valganciclovir for CMV retinitis.

He was subsequently discharged and was followed as an outpatient with close follow-up. Due to a slow decline in HIV viral load his ARV regimen was intensified to Truvada + Dolutegravir BID + Ritonavir boosted Darunavir. However, he continued to have persistent HIV viremia (see timeline and graphs below).

Despite this, the patient reported 100% adherence to his regimen and seemed to be tolerating his medications. Repeated HIV genotypic antiretroviral resistance testing (GART) showed a pan-susceptible virus with no treatment emergent resistance. Therapeutic drug monitoring was done for Dolutegravir, Darunavir and ritonavir which showed that the peak and trough levels of Darunavir and ritonavir were within normal limits, while Dolutegravir levels were on the spectrum of low-normal. Around this time, ART was briefly discontinued while awaiting the results of his therapeutic drug monitoring. Following this, his ART was restarted and his regimen was intensified to Truvada, Dolutegravir 50mg BID (increased for potential drug interactions), and standard dosing of Ritonavir boosted Darunavir. Additionally Doravirine 100mg twice daily was added to account for the drug interaction with Rifabutin. To address adherence, various strategies were used including the use of bubble-packs, directly observed therapy and intensive community pharmacy support. He was linked to our community case manager who would help him with transportation, attending clinic appointments as well as general supports such as housing.

He continued to have low level viremia. More concerning, he failed to immune reconstitute despite 18 months of effective ART.

In November 2019, the patient was noted by our case manager to have subacute onset cognitive deficits as well as new choreiform movements. He reported non-specific headaches. He scored 19/30 on a Montreal Cognitive Assessment with deficits in visuospatial and delayed recall. A CT scan of the head was conducted showing no abnormalities. Brain MRI showed: "Ventriculomegaly with diffuse bilateral periventricular white matter signal abnormalities, diffuse signal abnormality of the corpus callosum, periaqueductal gray matter and atrophy of mamillary bodies, and no MR features of opportunistic intracranial infection". These findings were felt to be in keeping with chronic changes secondary to alcohol abuse and HIV encephalitis. Further workup included: negative routine blood and urine cultures, MAC blood cultures, a sterile Lumbar puncture which was negative for Cryptococcus, CMV, HSV, VZV, Tuberculosis, toxoplasmosis, BK virus, and JC virus. Interestingly though, we did perform a quantitative HIV viral load on his CSF which revealed an HIV viral of 182,000 copies/ml. His simultaneous peripheral blood HIV viral load was 464copies/ml. An HIV GART analysis on the CSF virus revealed only a 106I NNRTI mutation and 10V PI mutation, neither conferring any significant resistance. CSF drug levels were pursued but abandoned due to a cost issue. The case was discussed with neurology who felt his cognitive deficits would be explained by HIV encephalitis +/- Marchiafava-Bignami disease, a progressive neurological disease related to alcoholism.

Due to a concern for CNS viral escape phenomenon, his ARV therapy was further intensified to Abacavir/Lamivudine/Dolutegravir (Triumeq), an additional Dolutegravir 100mg a day, twice daily (BID) Maraviroc, Doravirine, and BID ritonavir boosted Darunavir. The new regimen consisted of drugs with higher CPE score as well as higher doses to overcome any absorption issues. Unfortunately, both pill fatigue as well as his neurocognitive decline began to affect his adherence. Follow-up testing done during periods of adherence, showed improvement in his neurocognitive status (MoCA score 24/30) and a declining CSF HIV viral load. Additionally, his CD4 counts reached a peak of 99 in May 2020 and a simultaneously done HIV viral load reached a nadir of 58 copies/mL. We did perform a resistance genotype using deep sequencing on the CSF HIV virus from December 2019 which revealed only the L10V and V106I mutations.

Due to his neurocognitive changes, he has now been admitted to a long-term care home where he continues to receive his intensive ART along with his OI therapies. He continues to be followed closely by our team.

### Conclusion

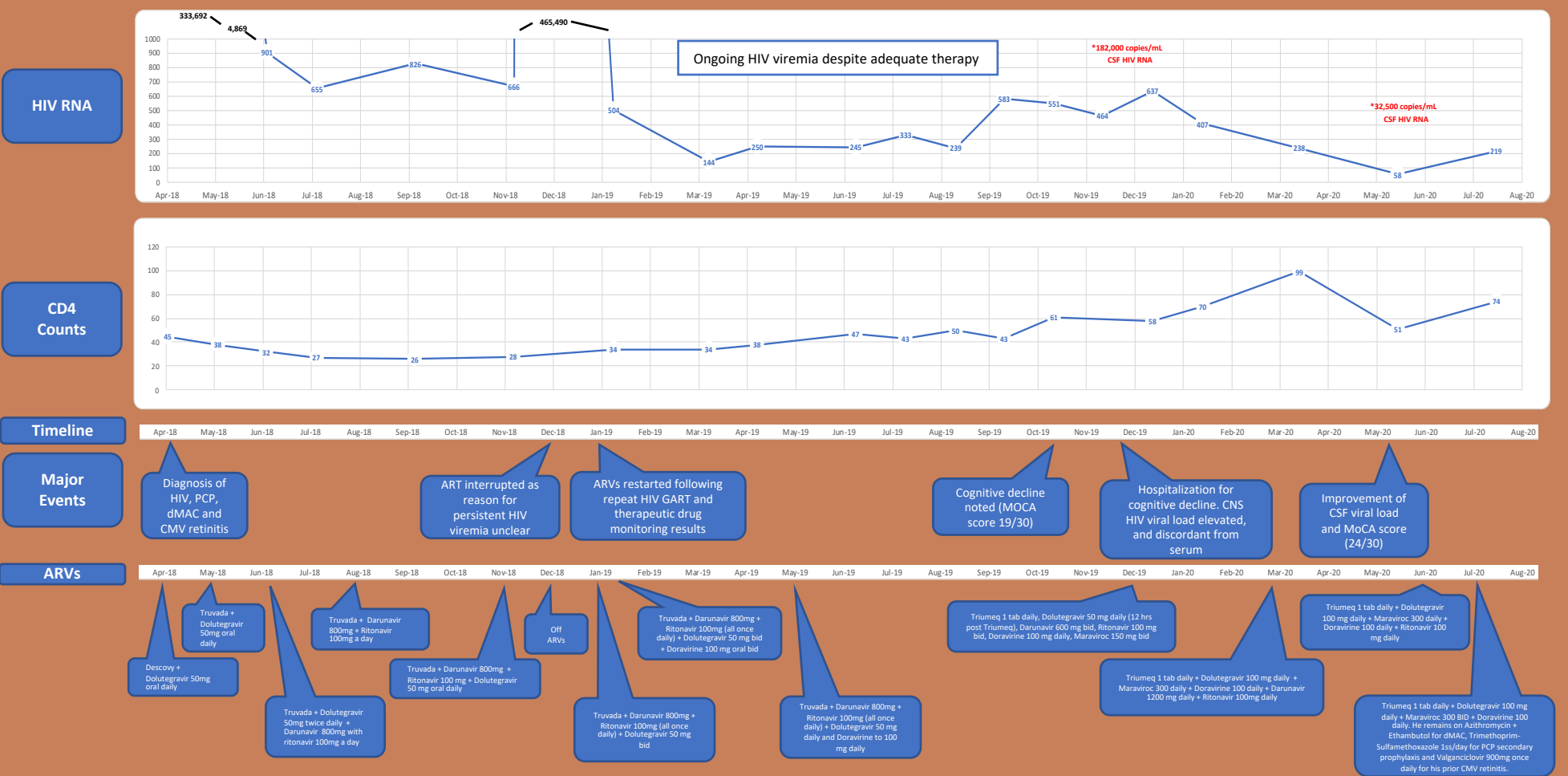
We think that the persistent HIV viral replication in the CNS compartment, despite standard ART, led to a neurocognitive decline in our patient related to ongoing HIV encephalitis and persistent peripheral blood HIV viremia.

Neurocognitive decline despite adequate treatment with ART is challenging to manage. Randomised controlled studies have thus far shown no improvements in cognitive function despite ART intensification with adjunctive therapies. Brain imaging, CSF HIV viral load measurement and genotyping plus input from neurology and psychology represent best practice.

This case also demonstrated that viral CNS escape can be a mechanism of persistent viremia, and should be considered when traditional causes of persistent viremia e.g. medication non-compliance, absorption, drug/drug interactions have been exhausted. Such patients are at risk of worsening adherence to ART and measures to support this should be part of standard practice.

### References

- Canestri, Ana, et al. "Discordance between cerebral spinal fluid and plasma HIV replication in patients with neurological symptoms who are receiving suppressive antiretroviral therapy." *Clinical Infectious Diseases* 50.5 (2010): 773-778.
- Edén, Anvd, et al. "HIV-1 viral escape in cerebrospinal fluid of subjects on suppressive antiretroviral treatment." *Journal of Infectious Diseases* 202.12 (2010): 1819-1823.
- Letendre, Scott, et al. "Validation of the CNS penetration-effectiveness rank for quantifying antiretroviral penetration into the central nervous system." *Archives of neurology* 65.1 (2008): 65-70.
- Tambassi, Giuseppe, et al. "Neurological symptoms during primary human immunodeficiency virus (HIV) infection correlate with high levels of HIV RNA in cerebrospinal fluid." *Clinical infectious diseases* 30.6 (2000): 962-965.
- Letendre, Scott, et al. "Validation of the CNS penetration-effectiveness rank for quantifying antiretroviral penetration into the central nervous system." *Archives of neurology* 65.1 (2008): 65-70.
- Eugenin, Elisav, et al. "Human immunodeficiency virus infection of human astrocytes disrupts blood-brain barrier integrity by a gap junction-dependent mechanism." *Journal of Neuroscience* 31.26 (2011): 9456-9465.
- Lambotte, Olivier, Kumar Deiva, and Marc Tardieu. "HIV-1 persistence, viral reservoir, and the central nervous system in the HAART era." *Brain pathology* 13.2 (2003): 95-103.
- Ellis RJ, Letendre S, Valda F et al. Randomized trial of central nervous system-targeted antiretrovirals for HIV associated neurocognitive disorder. *Clin Infect Dis* 2014; 58: 1015–1022.



Acknowledgment: We would like to thank our patient who kindly consented to have his case discussed at this forum.